CIRCULATORY AND LYMPHATIC SYSTEM

CARDIO VASCULAR SYSTEM

Structure of blood vessels

1. **Large artery or elastic artery**

- Arterial wall made up of three layers. That is tunica intima, tunica media and tunica adventitia.
- **Tunica intima** : it is made up of endothelium, subendothelial connective tissue and internal elastic lamina, it is not distinct from the tunica media.
- **Tunica media** : it is mainely made up of elastic fibers there is some loose connective tissue some smooth muscles are present. . External elastic lamina present between tunica media and tunica adventitia, it is not distinct from the tunica media.
- **Tunica adventitia** : it is relatively thin in large artery. It contain elastic fibers and vasa vasorum and collagen fibers.
- Eg : aorta, common carotid artery etc

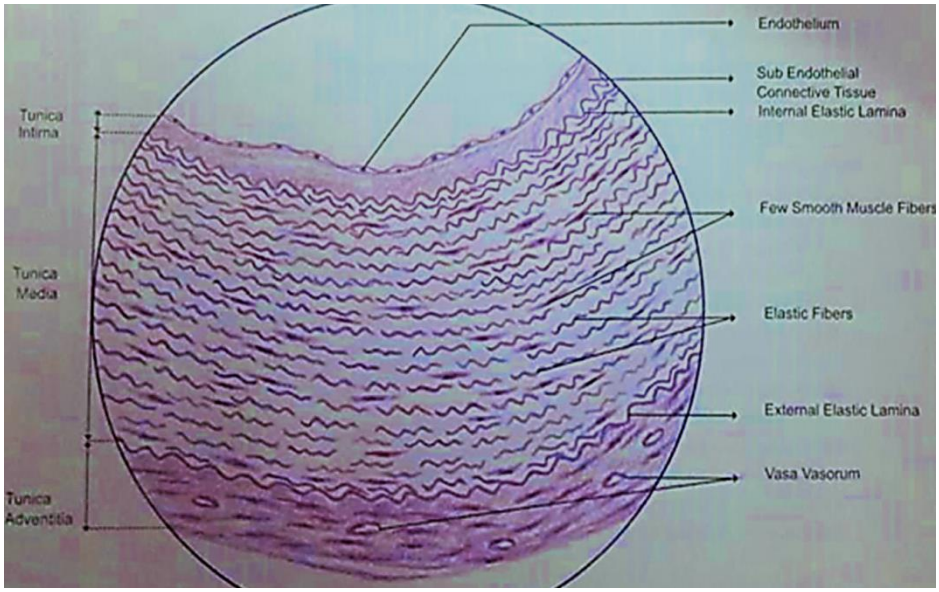

2. **Medium sized artery or muscular artery**

- **Tunica intima** : it is made up of endothelium, subendothelial connective tissue . Internal elastic lamina is present in between tunica intima and tunica media.
- **Tunica media** : it consist of mainely smooth muscle fibers and few elastic fibers. External elastic lamina seperates tunica media from tunica adventitia.
- **Tunica adventitia** : it consists of thin layers of fibroelastic tissue contain vasovasorum.
- **Eg** : radial and ulnar arteries

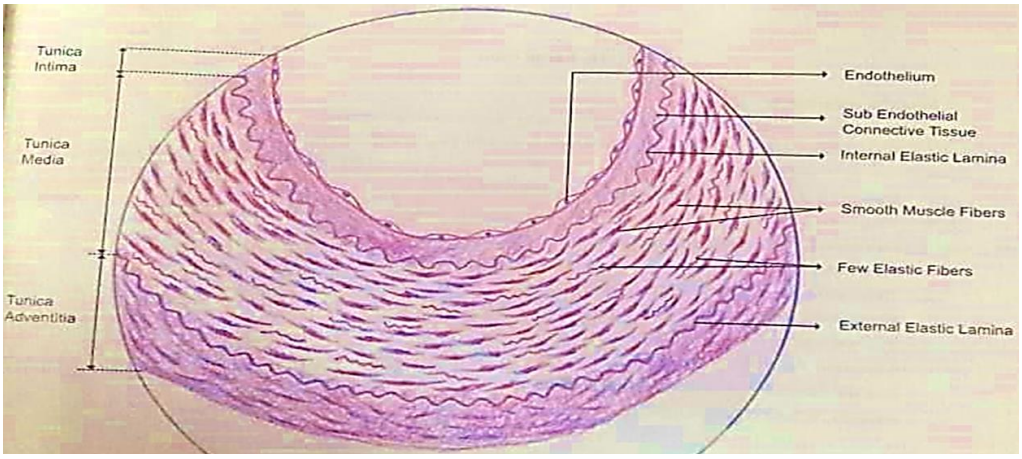

Large vein

It have thin wall and bigger lumen

- **Tunica intima :** consisting of endothelium, small amount of subendothelial connective tissue and internal elastic lamina.
- **Tunica media** : thin circular arrangement of smooth muscle fibers.
- **Tunica adventitia** : this layer is largely developed, smooth muscles in longitudinal arrangement as bundles, surrounded by connective tissue containing vasa vasoram.
- **Eg** : superior and inferior venacava

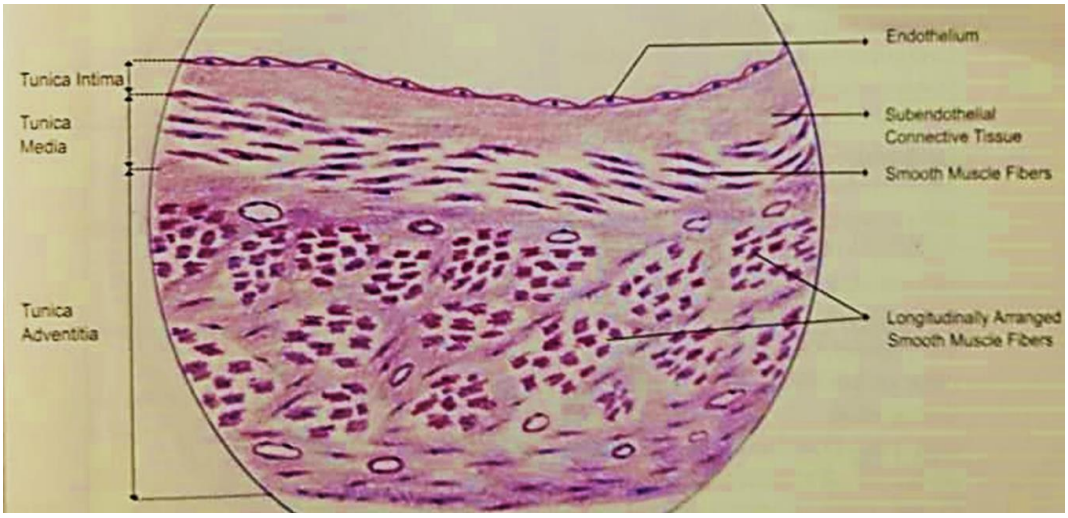

Medium sized vein

- Tunica intima, tunica media and tunica adventitia are present.
- Internal and external elastic lamina are absent.
- Tunica media contain few smooth muscle fibers, elastic and collagen fibers.
- Tunica adventitia consists of loose connective tissue, vasa vasorum and nerve fibers.
- Eg : saphenous and median cubital vein

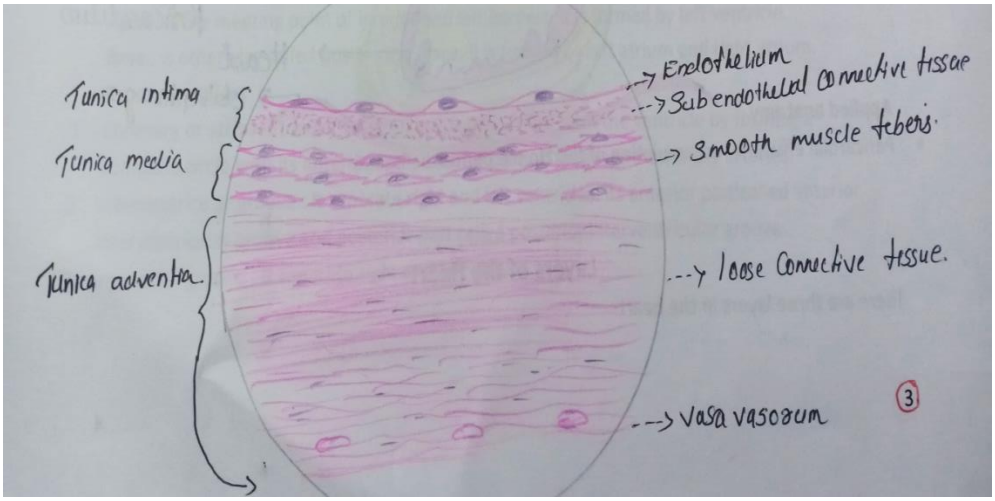

HEART

Coverings of heart (pericardium)

It is a fibrous sac. It has two parts

1. Fibrous pericardium : it is the outer layer of pericardium.
2. Serous pericardium : it is the inner layer and subdivided into outer parietal layer and inner visceral layer .

Pericardial cavity

It is a narrow space formed between parietal and visceral layer of serous pericardium. It contain serous fluid.

Relations

Anteriorly : sternum and sternopericardial ligament

Posteriorly : principal bronchi, esophagus and descending thoracic aorta

Contents

Heart

Great vessels : ascending aorta, pulmonary trunk, superior venacava, inferior venacava and pulmonary veins

	Fibrous and parietal pericardium	Visceral pericardium
Arterial supply	Internal and descending thoracic aorta	Coronary arteries
Venous drainage	Azygous vein and internal thoracic vein	Coronary sinus
Nerve supply	Phrenic nerve	Vagus and sympathetic nerve from T1 to T4

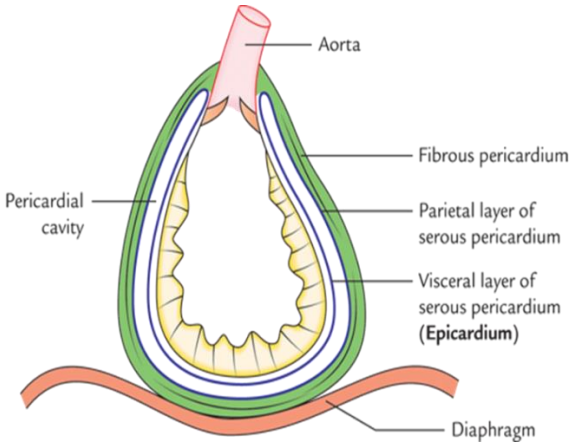

Applied anatomy

- Pericardial effusion : accumulation of fluid in the pericardial sac.

Layers of the Heart

There are three layers in the heart.

- **Epicardium** : it is the outer layer formed by visceral layer of serous pericardium, it formed by connective tissue covered by endothelium.
- **Myocardium** : it is the middle layer formed by the cardiac muscle, with branching, striped fibers joined by the intercalated disc. The muscle cells branch to form a network over whivh the electrical impulses can spread freely from cell to cell.
- **Endocardium** : it is the inner layer, consists of connective tissue covered by endothelium.

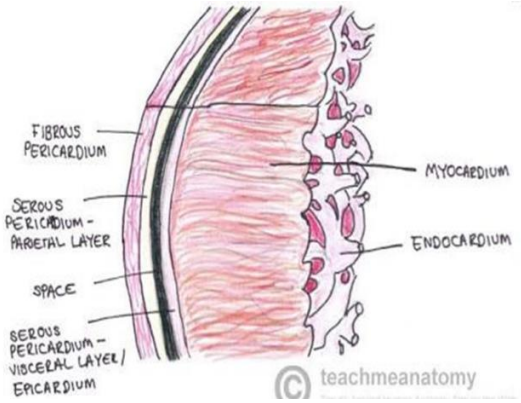

External Features of Heart

Heart is a conical hollow muscular organ. It pumps blood to the various part of the body. It consists of four chambers – right and left atrium and ventricles

Borders

1. Superior border : formed by right and left atrium
2. Right border : formed by right atrium
3. Inferior border : formed by right ventricle and left ventricle
4. Left border : left ventricle and left auricle

Surfaces

1. Anterior or sternocostal surface : is formed by right and left atrium and ventricles.
2. Diaphragmatic or inferior surface : is formed by right and left ventricles.
3. Left surface : is formed by left ventricle and auricle .

Apex : is the meeting point of inferior and left borders. It is formed by left ventricle.

Base : is otherwise called posterior surface. It is formed by left atrium and right atrium.

Groove or sulcus

1. Coronary or atrioventricular sulcus : It separate atrium from the ventricle by forming a complete circle with its anterior and posterior parts. It lodges the coronary arteries.
2. Interventricular groove : It separate right and left ventricles. Its anterior part called anterior interventricular groove and posterior part called posterior interventricular groove.
3. Interatrial groove : It separate right and left atrium.

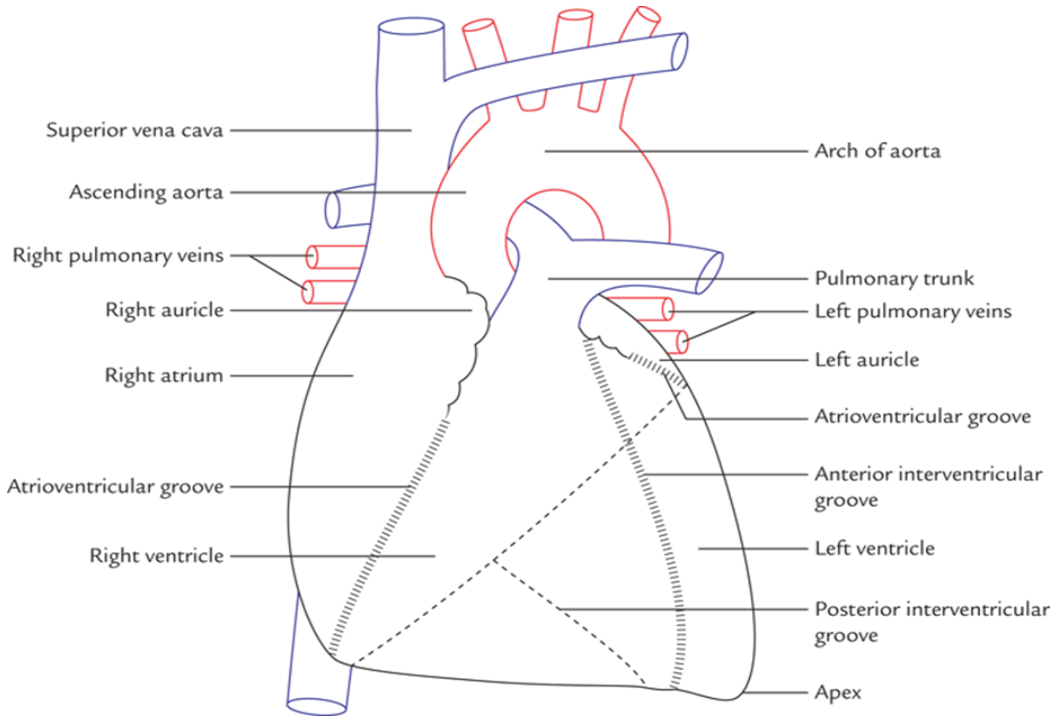

External and Internal features of Right Atrium

Right upper chamber of heart . It receives venous blood mainly from superior venacava, inferior venacava and coronary sinus. It pumps blood into right ventricle through tricuspid opening, it guarded by tricuspid valve.

External features

- Right atrium forms sternocostal surface, base, right border and superior border.
- It is vertically elongated chamber.
- An ear shaped projection present in its anterosuperior part called right auricle.
- On the right border of atrium, a sulcus pass from superior venacava to inferior venacava known as sulcus terminalis. It is formed by muscular ridges known as crista terminalis.

Internal features

- Interior of right atrium divided into two parts .

1. **Smooth posterior part** : It consist of

- superior venacava opens at its upper end and inferior venacava at its lower end.
- Opening of inferior venacava is guarded by a valve called Eustachian valve or valve of inferior venacava.
- Opening of coronary sinus is present between opening of inferior venacava and right atrioventricular orifice, which is guarded by a valve called valve of coronary sinus.
- Fossa ovalis : Oval shaped depression present in the interatrial septum, that is the remnant of foramen ovale.
- Annulus ovalis : It is a prominent margin of fossa ovalis.

2. **Rough anterior part** : present transversally running muscular ridges called musculi pectinati. Ridges arising from the crista terminalis.

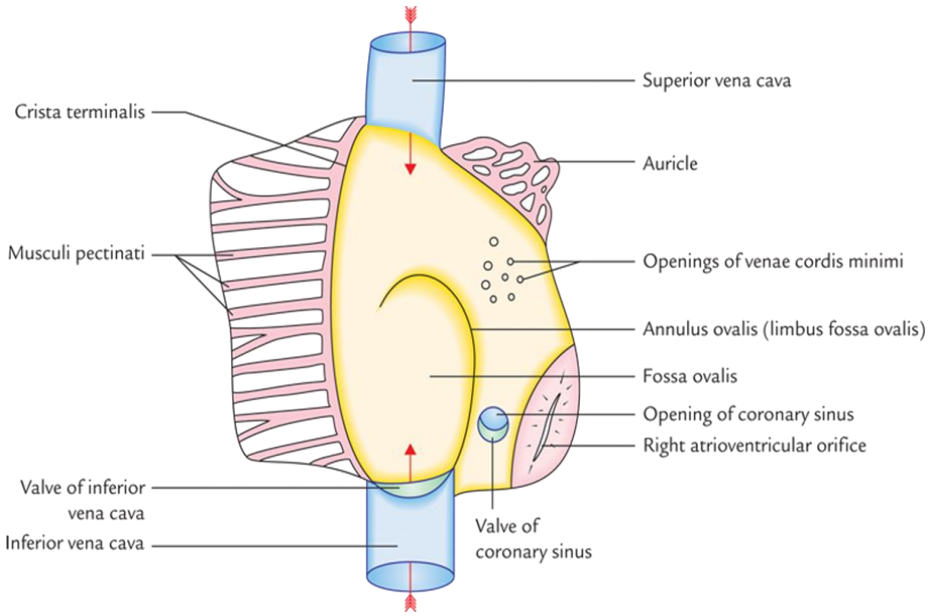

Left Atrium

It receives pure blood from lungs through four pulmonary veins. It pumps blood into the left ventricle through bicuspid orifice. This orifice is guarded by a valve called bicuspid valve. It forms left border, superior border, sternocostal surdace, base and left surface. Its interior all the parts are smooth except at the auricle. Auricle present muscular pectinati. Its interatrial septum present oval depression called fossa lunata.

Difference between right and left atrium

Right atrium	Left atrium
It forms the right upper chamber of the heart. It located on the right side.	It forms the left upper chamber of the heart. It located on the left side.
It receives blood from the body through inferior venacava, superior venacava and coronary sinus	It receives blood from the lungs through four pulmonary veins
It receives deoxygenated blood	It receives oxygenated blood
It supplies blood to the right ventricle through right atrioventricular valve or tricuspid valve	It supplies blood to the left ventricle through left atrioventricular valve or bicuspid valve
It involved in the systemic circulation	It involved in the pulmonary circulation

Difference between right and left ventricles

Right ventricle	Left ventricle
Receives blood from right atrium	Receives blood from left atrium
Pumps blood into lungs through pulmonary trunk	It pumps blood into aorta
It forms sternocostal surface, inferior border and diaphragmatic surface	It forms apex, sternocostal surface, diaphragmatic surface, left surface and left border
Wall are less thicker	Wall are 3 times thicker
Internal features	
It has an inflowing and outflowing part	Same
In flowing part	

Inflowing part contain muscular ridges called trabeculae carneae. They are of three types – bridges, ridges and papillary muscles. Papillary muscle attached into atrioventricular valve through chordae tendineae.	Same
Papillary muscles are anterior, posterior and septal	Papillary muscles anterior and posterior
Atrioventricular orifice is guarded by tricuspid valve	Atrioventricular orifice is guarded by bicuspid valve
Out flowing part	
Pulmonary orifice guarded by pulmonary valve	Aortic orifice guarded by aortic valve
Smooth and give rise to pulmonary trunk	Smooth and give rise to aorta

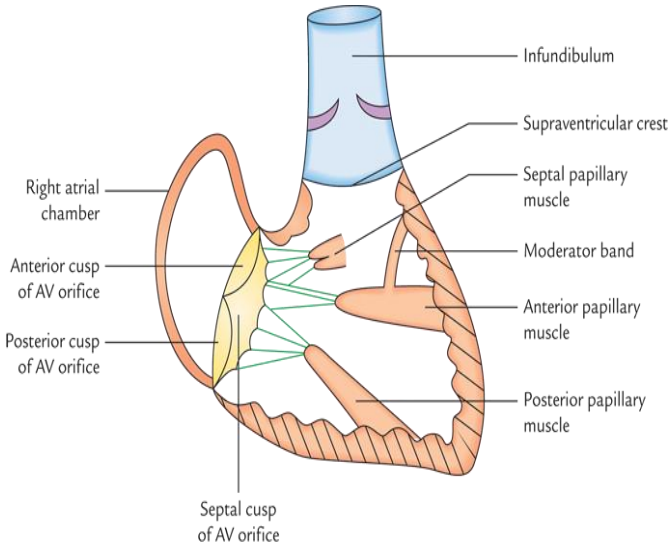

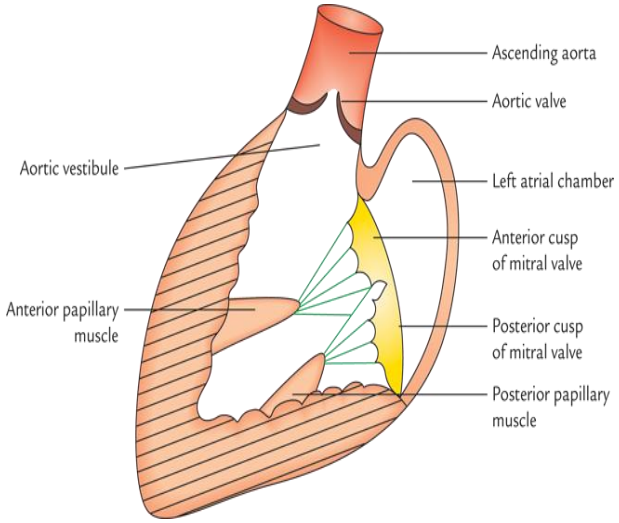

Valves of the heart

Right atrioventricular valve	**Left atrioventricular valve**
It is also known as tricuspid valve. It has three cusps – anterior, posterior & septal. Cusps is formed by a duplication of endocardium enclosing collagenous tissue. It presents an attached margin & a free margin and ventricular surface and an atrial surface. Papillary muscle attached into atrioventricular valve through chordae tendineae.	It is also known as bicuspid or mitral valves. The components of mitral valves are collagenous ring of the orifice, anterior & posterior cusps are attached into anterior & posterior papillary muscles. papillary muscles attached into mitral valve through chordae tendineae.

Pulmonary valve	Aortic valve
Valves or cusps are semilunar in shape. Cusps are right anterior, left anterior & posterior. The free margin of each cusp presents a localized thickening called nodule & thin margin called lunule. Situated between pulmonary trunk rifice & right ventricle	Valves or cusps are semilunar in shape. It is located between aortic orifice & left ventricle. It consists of three cusps – right posterior, left Posterior & anterior.

Applied anatomy

Murmurs : the abnormal heart sounds are called murmurs. They are produced due to regurgitation blood heard when the valves are either stenosed or when the valves are not closed properly.

Mitral stenosis : it is most common in young age. Usually there is a history of rheumatic fever in the childhood in these cases. These lead to rise in the left atrial pressure & enlargement of left atrium which may press on the esophagus.

Blood supply of Heart

Arterial supply

Right coronary artery	Left coronary artery
Smaller	Larger
Origin	
Right anterior aortic sinus of ascending aorta	left posterior aortic sinus of ascending aorta
Course	
First part – runs anteriorly and to the right between pulmonary trunk and right auricle.	Passes to the left between pulmonary trunk and left auricle
Second part – run downward in the anterior part of coronary sulcus between right atrium and ventricle. Reaches the inferior margin of the heart.	Left coronary artery divides into two terminal branches while it behind the pulmonary trunk, into circumflex and anterior interventricular artery
Third part – lies in the right posterior part of atrioventricular groove on the diaphragmatic surface and end by anastomosing with circumflex Part of left coronary artery. Just before anastomosing it give a branch called posterior interventricular branch.	**Circumflex branch** – runs to the left anterior coronary suclcus and reaches the left border, then it winds round the left border and runs in the left posterior coronary sulcus and end by anastomosing with right coronary artery. **Anterior interventricular branch** – runs downwards in the anterior interventricular groove and reaches

	the apex of heart, winds round in the inferior border and runs posterior interventricular groove and anastomoses with posterior interventricular branch of right coronary artery.
Branches	
Posterior interventricular, marginal, nodal, right and infundibular branches	Anterior interventriular, left atrial and pulmonary Branches.
Area of distribution	
Right atrium and ventricle, left ventricle near adjoining part of posterior interventricular groove and septum and conducting system of heart.	Left atrium and ventricle, right ventricle near adjoining part of anterior interventricular groove and septum and left branch of AV bundles

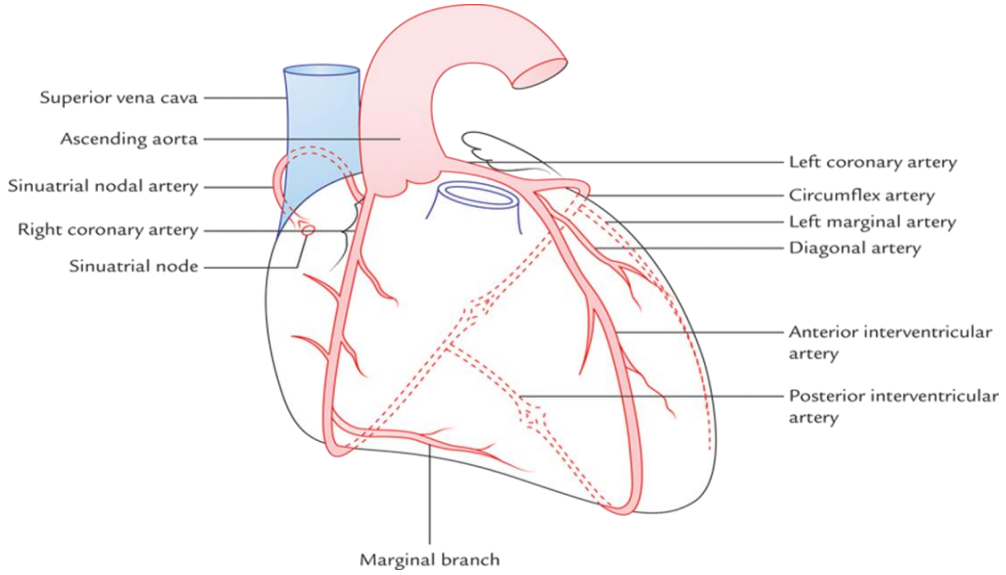

Applied anatomy

- **Angina pectoris** : if the arteries are narrowed, the blood supply to the cardiac muscle reduced. This results, severe pain in the left pericardium, that last as long as 20 minutes. This pain radiated to the AW left shoulder and medial side of arm and forearm.
- **Myocardial infraction** : A sudden block of one of the larger coronary artery usually leads to myocardial ischemia followed by myocardial necrosis. This stop functioning of heart and cause death. This condition is called heart attack.

Veins of Heart :

They are

- **coronary sinus** : It is the largest vein of heart. 3cm long. Most of the veins draining the heart opens into coronary sinus. Located in the left posterior coronary sulcus. It opens into right atrium.
- great cardiac vein, middle cardiac vein, small cardiac vein, right marginal vein, oblique vein of left atrium, posterior vein of left ventricle and anterior cardiac vein. These veins are called tributaries of coronary sinus.
- Venae cordis minimi, it is the smallest cardiac vein present in all chambers of heart.

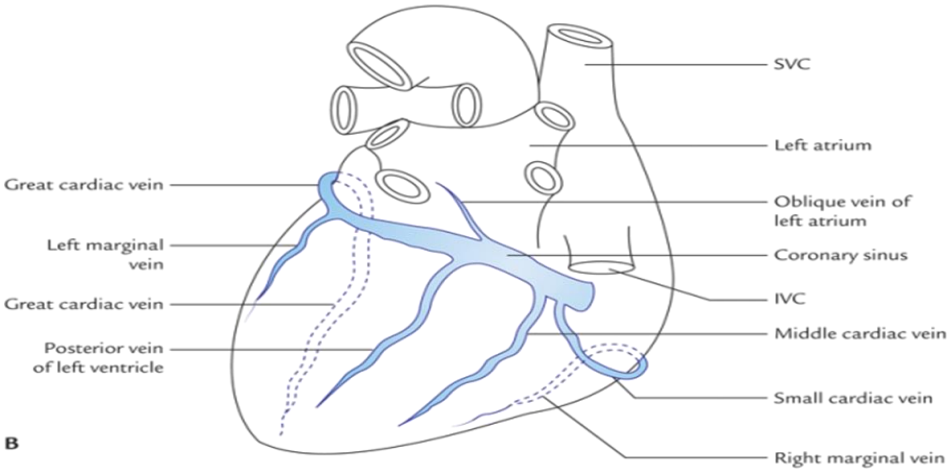

Nerve supply of heart

Sympathetic & parasympathetic through superficial & deep cardiac plexuses.
Parasympathetic – vagus, they are cardioinhibitory
Sympathetic – derived from upper 3 to 5 thoracic spinal segments, they are cardioacceleratory
Superficial cardiac plexus – formed by left cervical sympathetic trunk & left vagus nerve.
Deep cardiac plexus – formed by 3 cervical & upper 4 or 5 thoracic ganglia of sympathetic chains & cardiac branches of vagus & recurrent laryngeal nerve.

<u>Arteries of upper limb</u>

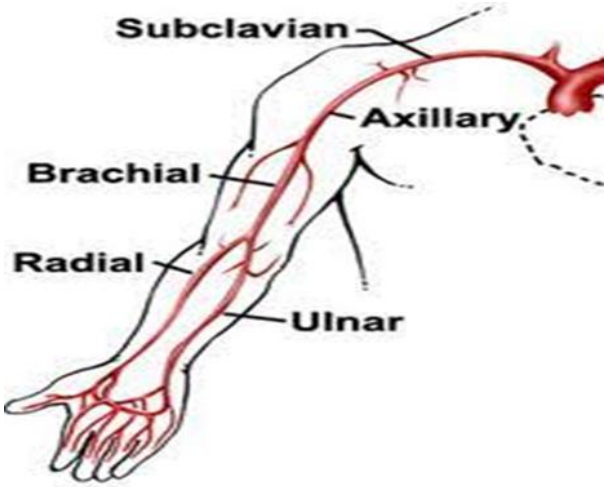

Artery	Origin	Branches & distribution	Termination
Axillary artery	Continuation of subclavian artery beyond the outer border of the 1st rib	a. Superior thoracic artery b. Thoracoacromial artery c. Lateral thoracic Artey d. Subscapular artery e. Anterior & posterior circumflex humeral arteries • Supplies the walls of the axilla, breast & shoulder joir	Termination by continuing as the branchial artery at the lower border of the teres major
Brachial artery	Continuation of the axillary artery beyond the lower border of teres major muscle	a. Profunda brachii artery b. Muscular branches c. Superior & inferior ulnar collateral d. Radial artery e. Ulnar artery • Supplies muscles of Arm & elbow joint	Terminate by Dividing in the cubital fossa into the radial & ulnar arteries
Radial artery	Terminal branches of the brachial artery	a. Radial recurrent artery b. Superficial & deep palmar branches c. 1st dorsal metacarpal artery d. Radialis indices artery e. Princeps polices artery • Supplies the elbow joint, wrist joint, muscles of the forearm, palm & 1st & 2nd digits.	Terminating by the formation of Superficial & deep palmar arches
Ulnar artery	Terminal branch of brachial artery	a. Anterior & posterior Ulnar recurrent arteries b. Common interosseous artery c. Muscular branches d. Superficial & deep palmar branches	Terminating by the formation of Superficial & deep palmar arches

		• Supplies the elbowjoint, wrist joint, muscles of the forearm & palm	

Arteries of Thorax

Artery	Origin	Branches & distribution	Termination
Pulmonary trunk	Right ventricle	• Right & left pulmonary arteries • Carries deoxygenated blood to the lungs for oxygenation	Terminates by dividing into two pulmonary arteies
Ascending aorta	Left ventricle	• Right & left coronary arteries • Supplies the heart	Terminates by arch of aorta
Arch of aorta	Continuation of ascending aorta	a. Brachiocephalic trunk b. Left common carotid artery c. Left subclavian Artery • Supplies head, neck, brain & upper limb	Terminates by descending thoracic aorta
Descending thoracic aorta	Continuation of t arch of aorta	a. Posterior intercostal artery b. Bronchial arteries c. Oesophageal arteries • Supplies the chest wall, lung & esophagus.	Terminates by abdominal artery
Internal thoracic artery	Branch of subclavian artery	a. Anterior intercostal arteries b. Musculophrenic artery c. Superior epigastric artery	Terminates by dividing into musculophrenic &

		• Supplies anterior chest wall, breast, anterior abdominal wall & diaphragm	superior epigastric arteries

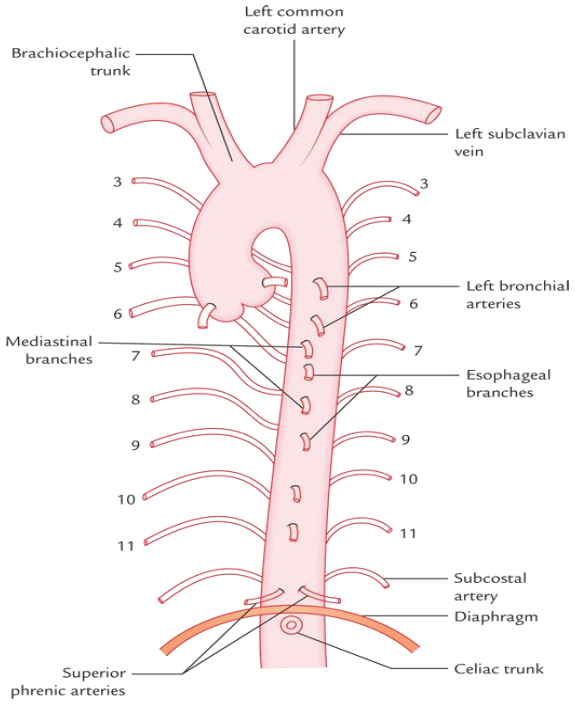

Arteries Of Head and Neck

Artery	Origin	Branches & distribution	Termination
Common carotid Artery	Arises from the brachiocephalic trunk on the right side & the arch of aorta on the left side	a. External carotid artery b. Internal carotid artery	Terminates by dividing into externa & internal carotid arteries
External carotid artery	Arising from the common carotid artery	a. Superior thyroid artery b. Lingual artery c. Facial artery d. Occipital artery e. Posterior auricular artery f. Ascending pharyngeal artery	Terminates by dividing into maxillary & superficial temporal arteries

		g. Maxillary artery h. Superficial temporal artery • supplies the scalp, face, oral cavity, salivary glands, tongue, pharynx, nasal cavity thyroid gland & external ear	
Internal carotid artery	Arising from the common carotid artery	a. Superior & inferior hypophyseal arteries b. Ophthalmic artey c. Posterior communicating artery d. Anterior choroidal artery e. Anterior cerebral artery f. Middle cerebral artery g. Meningeal branches • Supplies the brain through circle of Willis, eye & pituitary gland.	Terminates by dividing into anterior & middle cerebral arteries

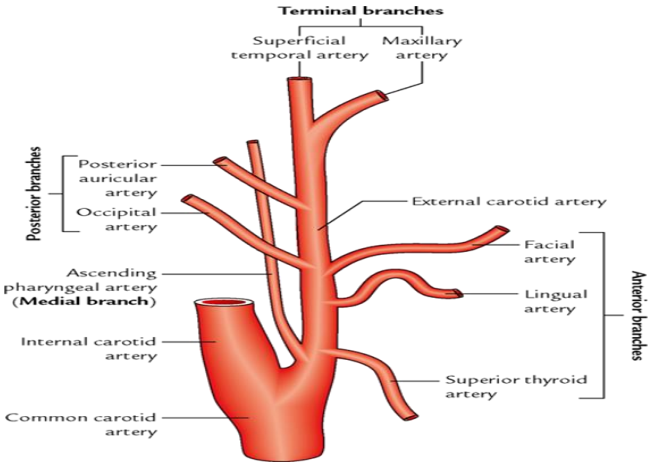

Arteries of Abdomen

Abdominal aorta

Ventral or anterior branches		
Main branch	Subdivision	Area of supply
Coeliac trunk –	Left gastric artery	Stomach and esophagus

artery of foregut	Hepatic artery	Stomach, duodenum, pancreas, liver and gallbladder
	Splenic artery	Spleen, stomach and pancreas
Superior mesenteric artery – artery of midgut	Inferior pancreatico duodenal artery	Pancreas and duodenum
	12 to15 jejunal and ilial Branhes	Jejunum and ilium
	Ileocolic artery	Caecum, appendix and terminal part of ileum
	Right colic artery	Ascending colon
	Middle colic artery	Transverse colon
Inferior mesenteric artery – artery of hind gut	Left colic artery	Transverse and descending colons
	Sigmoid artery	Sigmoid colon
	Superior rectal artery	Rectum and anal canal.
Lateral branches		
Right and left inferior Phrenic arteries		Diaphragm
Right and left middle Suprarenal arteries		Kidney and suprarenal glands
Right and left renal arteries		Kidney and suprarenal glands
Right and left gonadal arteries		Testes and ovary
Dorsal or posterior branches		
4 pairs lumbar arteries		Posterior abdominal wall
Medial sacral artery		Sacral region
Terminal branches		
Right and left common iliac arteries		

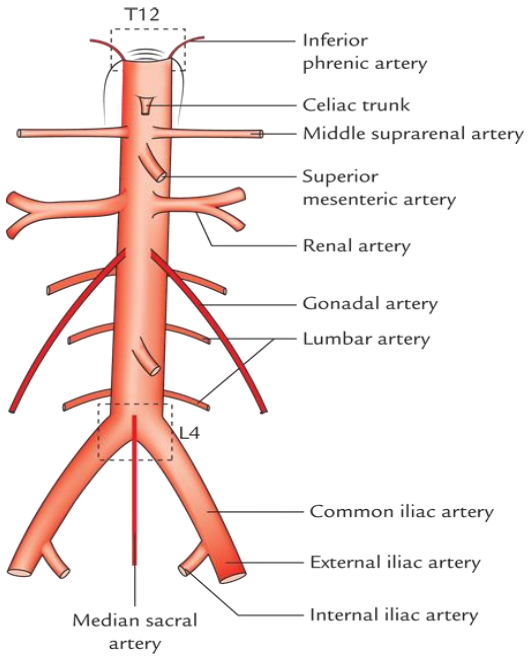

Arteries of Pelvis

Internal iliac artery

Branches from anterior division	
Branches	**Area of supply**
Superior vesical artery	Urinary bladder
Middle rectal artery	Rectum
Vaginal artery	Vagina, urinary bladder and urethra
Inferior vesical artery	Only supply male for urinary bladder, Prostate, seminal vesicle and ductus deferense
Inferior gluteal artery	Gluteal region
Obturator artery	Medial side of thigh
Internal pudental artery	Perineal region
Branches from posterior division	
Superior gluteal artery	Gluteal region
Iliolumbar artery	Lumbar region and sacroiliac joint
Lateral sacral artery	Content of sacral canal

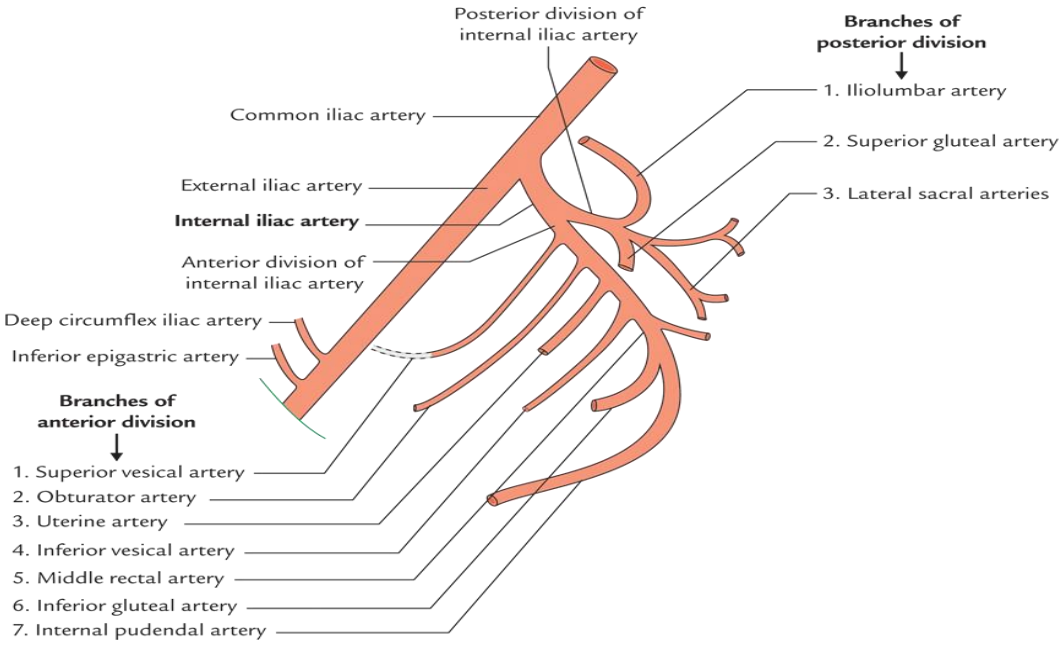

Arteries of Lower Limb

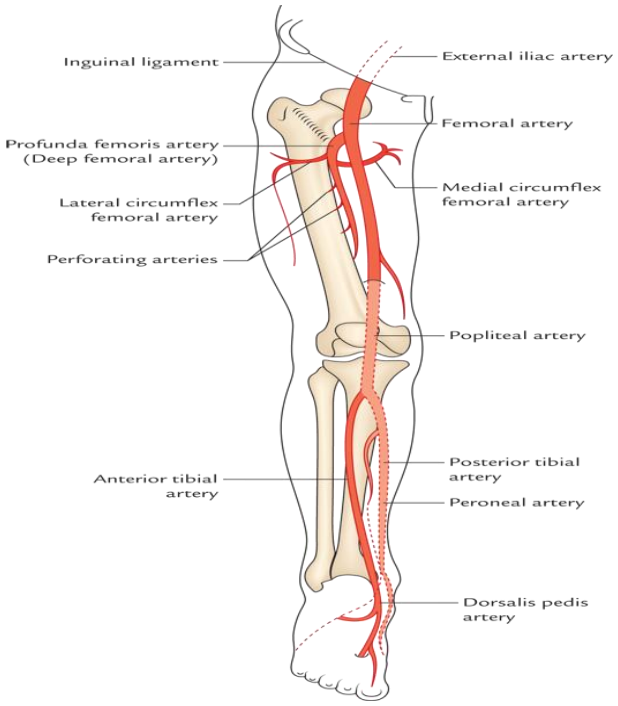

Artery	Origin	Branches & distribution	Termination
Femoral artery	Continuation of external iliac artery	a. Superficial epigastric artery b. Superficial & Deep external pudental arteries c. Superficial	

		circumflex iliac artery d. Profunda femoris artery e. Descending genicular artery • Supplies muscles of thigh, lower part of anterior abdominal wall, hip joint & knee joint	
Popliteal artery	Continuation of femoral artery	a. Genicular branches b. Anterior tibial artery c. Posterior tibial artery • Supplies knee joint through its genicular branches	Terminates by dividing into anterior & posterior tibial arteries
Anterior tibial artery	Terminal branch of popliteal artery	a. Anterior & posterior l tibial recurrent arteries b. Muscular branches c. Medial & lateral malleolar arterie • Supplies knee joint, ankle joint, muscles of the anterior compartment of leg & dorsum of the foot through the dorsalis pedis arteries	Terminates by continuation of dorsalis pedis artery into the dorsum of the foot
Posterior tibial artery	Terminal branch of popliteal artery	Peroneal artery Muscular branches Medial plantar artery Lateral plantar artery Supplies the muscles of the posterior & lateral compartment of leg, ankle joint, sole of the foot	Terminates by dividi into medial & lateral plantar arteries

Clinical anatomy of arterial system

Artery	Clinical anatomy
Arch of aorta	localized dilatation of arch of aorta called aortic aneurysm
Brachial artery	The blood pressure is recorded by auscultating the brachial artery in the cubital fossa.
Radial artery	It can be used for radial pulse on the anterior surface of lower end of radius.
Femoral artery	• It is superficial in the femoral triangle, so it can be used for cannulation. • Cardiac and renal angiography, a long slender catheter inserted into femoral artery, in the femoral triangle.
Popliteal artery	Blood pressure in the lower limb recorded from the popliteal artery.
Dorsalis pedis artery	Pulsation of the dorsalis pedis artery felt in the midway between two malleoli.

Vein Used For Intravenous Injections

1. Dorsal venous arch

- It is a network of veins on the dorsal surface of hand.

Tributaries

1. Three dorsal metacarpal veins.
2. A dorsal digital vein of medial side of little finger .
3. A dorsal digital vein of lateral side of index finger.
4. Two dorsal digital veins of the thumb.

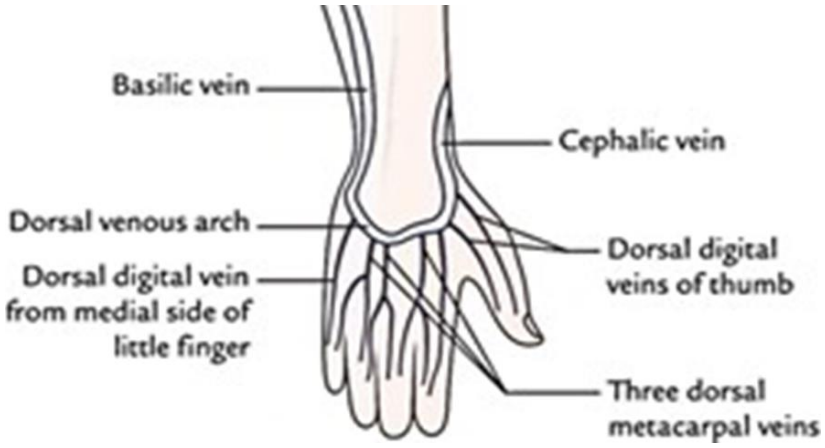

2. Cephalic vein

- It is the continuation of lateral end of dorsal venous arch. It run along the lateral side of hand , forearm and arm. It pierces the clavipectoral fascia and drains in to the axillary vein.

3. Median cubital vein

- It is the communicating venous channel between the cephalic and basilica vein. It shunts blood from the cephalic vein to basilica vein. It begins from the cephalic vein 2.5cm below the elbow and ends into the basilica vein, 2.5cm above the elbow . It separated from the brachial artery by the bicipital aponeurosis. It communicates with deep veins through the perforator vein. It receives median vein of the forearm. It runs obliquely upward and medially infront of the elbow.

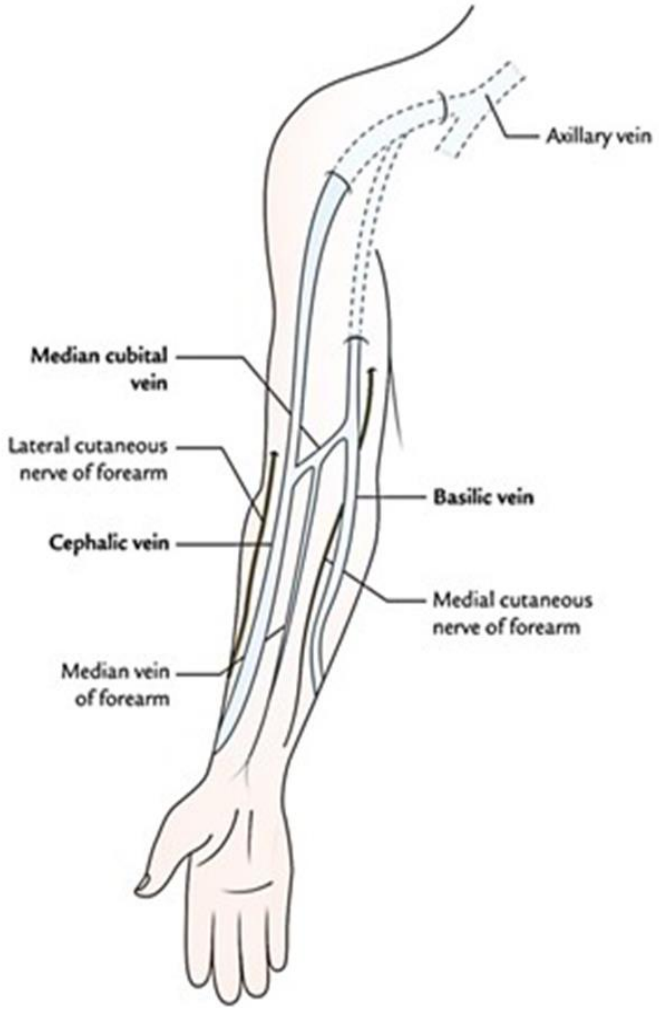

4. Great saphenous vein

- It is the largest vein in the body.
- **Formation** : Medial end of dorsal venous arch of the foot and medial marginal vein of the foot.
- **Course** : it runs upward and medially to reach the posteromedial aspect of the knee joint. It ascends from it and reaches up to the level of saphenous opening by piercing the crimbriform fascia. It consists of 10 to 20 valves.
- **Termination** : it drains into femoral vein.

Sites	Tributaries
At the commincement	Medial marginal vein of great toe.
In the leg	Short saphenous vein, deep vein, posterior arch vein
Just below the knee	Anterior vein of leg, vein from the calf
In the thigh	Anterolateral vein, posteromedial vein
Just before piercing crimbriform fascia	Superficial epigastric vein, superficial circumflex iliac vein, superficial external pudental vein
Just below the termination in the femoral vein	Deep external pudental vein

Clinical anatomy

Varicose vein : incompetency of the valves causes vein become dilated and tortuous they are called varicose vein

Great saphenous vein graft : in coronary bypass surgery to relive ischemia of the heart, a segment of great saphenous vein is removed and used for aortocoronary grafting to bypass an arterial obstruction

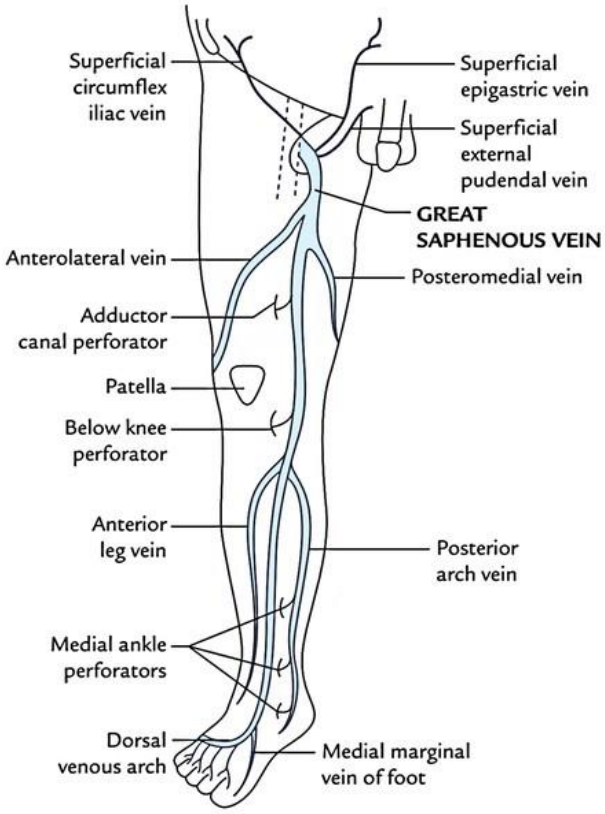

5. Femoral vein

It is the upward continuation of popliteal vein and continued as external iliac vein .

Course : Begins at the lower end of adductor canal. Ascends up in the adductor canal and enters femoral triangle.

Tributaries : Great saphenous vein, profunda femoris vein, medial and lateral circumflex vein and deep external pudental vein .

Applied anatomy

Femoral vein is the most commonly used vein for intravenous infusion in case of peripheral circulatory failure in infants.

Femoral vein is also used to insert catheter into right atrium and ventricle to measure pressure.

6. Internal jugular vein

Formation : It is the direct continuation of sigmoid sinus.

Termination : It drains into subclavian vein.

Tributaries : Inferior petrosal sinus, pharybgeal vein, common facial vein, lingual vein, superior thyroid vein and middle thyroid vein.

Applied anatomy

Internal jugular vein is commonly used for central venous access for measuring pulmonary artery pressure, prolonged intravenous feeding and for introduction of cardiac pacemaker.

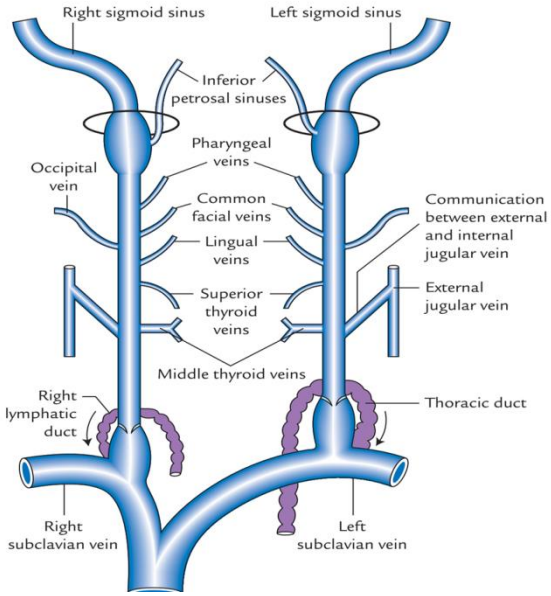

Subclavian vein

It is the continuation of axillary vein .

Extend : Outer border of first rib to the medial border of scaleneus anterior .

Termination : It joins into internal jugular vein to form brachiocephalic vein.

Tributaries : External jugular vein and dorsal scapular vein .

Applied anatomy

Subclavian vein is commonly used for measure intracardiac pressure .

Difference between

Artery	Vein
Thick walled	Thin walled
More muscular	Less muscular
More elastic	Less elastic
Smaller lumen	Larger lumen
Tunica media thicker than tunica adventitia	Tunica media thinner than tunica adventitia
No valves in lumen	Valves in lumen

Pulmonary circulation	Systemic circulation
It carries deoxygenated blood from the right ventricle of the heart to the lungs through the pulmonary artery	It carries oxygenated blood from the left ventricle of the heart to the rest of the body by the aorta
It carries oxygenated blood from the lungs to the left atrium of the heart by the pulmonary vein	It carries deoxygenated blood from the body to the right atrium of the heart by the superior and inferior venacava
Composed of pulmonary artery and pulmonary vein	Composed of superior and inferior venacava, aorta and other small blood vessels
Carries blood to the lungs	Carries blood through out the body

Questions

1. Structure of blood vessels and one region major arteries
2. Heart – external features, chambers, blood supply, nerve supply, valves and applied anatomy
3. Right atrium
4. Right ventricle
5. Pericardium or layers of heart
6. Coronary arteries

7. Coronary sinus
8. Medial cubital vein
9. Saphenous vein
10. External carotid artery
11. List the arteries of upper limb
12. List the arteries of lower limb
13. List the arteries of thorax
14. List the arteries of abdomen and pelvis
15. List the arteries of head and neck
16. List the vein used for intravenous injection
17. Difference between right and left atrium
18. Difference between right and left ventricles
19. Difference between right and left coronary arteries
20. Difference between pulmonary and systemic circulations
21. Difference between artery and vein

Lymphatic system

It is associated with cardiovascular system. It consists of lymphoid tissue or organs and lymphatic vessels .

Lymph

A part of tissue fluid, return to the circulation through lymphatic vessels. This clear fluid is the lymph and the vessels are the lymphatics.

Lymphatics

These begins as blind ended thin walled capillaries. They join to form larger vessels and traverse through group of lymph nodes.

Lymph node : Remove unwanted materials .

Lymphatic tissue or organ : Collection of lymphoid tissue are spleen, thymus and tonsils .

Lymph node

It is a bean shaped structure. It consists of one concave surface and one convex surface.

Through concave surface blood vessels enter into the node and lymphatics leave from the node (efferent vessels)

Through its convex surface lymph vessels (afferent) enters into the lymph node.

Lymph node has outer fibrous capsule made up of connective tissue. This capsule sends trabeculae inside. There is distinct subcapsular space.

It consists of outer cortex and inner medulla.

Afferent lymphatics around the gland pierces the capsule and drains into subcapsular space.

Cortex contains lymphoid follicles with pale staining germinal center. Rim of the follicles have densely packed inactive ‘B’ lymphocytes. Germinal center contains pale staining large, rapidly dividing ‘B’ lymphocytes.

Para cortex, which is the junction between cortex and medulla contains ‘T’ lymphocytes.

In medulla lymphocytes arranged like branching cords along the sinuses called as medullary cords. These are mainly macrophages and plasma cells.
Lymph will drain out from the hilum through the efferent lymphatics.

Major group of lymph nodes

Drainage area	Lymph nodes
Inguinal region	Superficial and deep inguinal nodes
Head and neck	Submandibular, cervical, parotid, submental and subclavicular nodes
Axilla	Axillary lymph nodes
Thorax	Internal thoracic, intercostal, mediastinal and tracheobronchial nodes
Abdomen and pelvis	Para aortic, hepatic, coeliac, mesenteric, gastric, internal and external iliac nodes

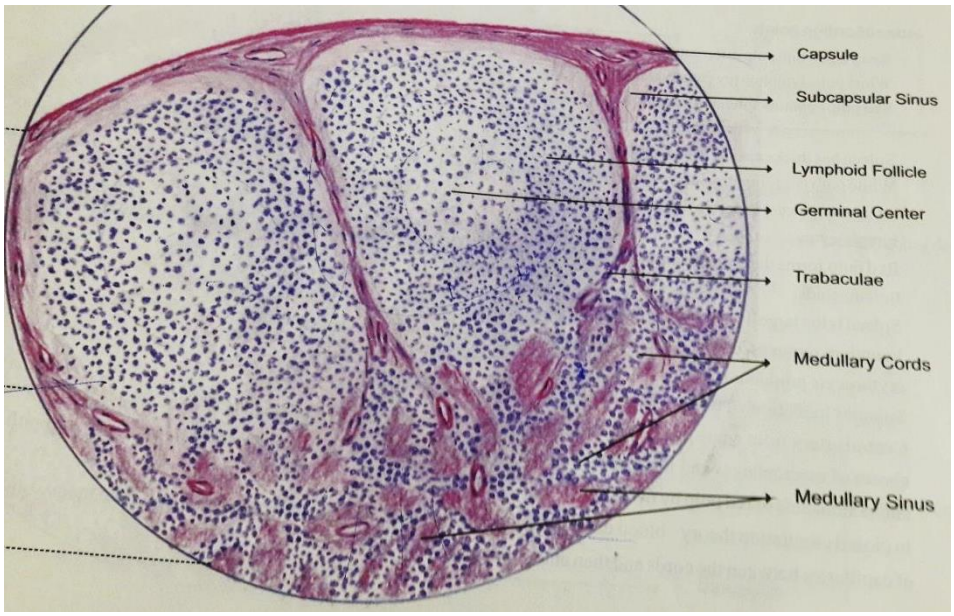

SPLEEN

Largest lymphatic organ in the body.
Location : Left hypochondrium and epigastrium
Shape : Wedge

Two ends : anterior and posterior
Three borders : superior, inferior and intermediate
Two surfaces : diaphragmatic and visceral
Anterior end : It is broad and border like. It is related to left colic flexure and phrenico colic ligament.
Posterior end : it is blunt and rounded. It is related to the upper pole of left kidney.
Superior border : Is convex and thin. It separates visceral surface from diaphragmatic surface. This border present one or two notches near its anterior end.
Inferior border : It is rounded. It seperates visceral surface from diaphragmatic surface.
Intermediate border : It is rounded. It separates gastric impression from the renal impression on the visceral surface.
Diaphragmatic surface : Smooth and convex.
Visceral surface : Concave and irregular.

Relations

Peritoneal relations	Visceral relations
Spleen is covered by peritoneum except at its hilum. Hilum two peritoneal folds are attached 1. Gastrosplenic ligament : extent from hilum of spleen to the greater curvature of stomach. 2. Lienorenal ligament : extent from hilum of spleen to anterior surface of left kidney	**Visceral surface** 1. Gastric impression for fundus of stomach lies between the superior and intermediate borders. 2. Renal impression for left kidney lies between intermediate and inferior Border. 3. Colic impression for left colic flexure. Consist of triangular area adjoining the anterior end of spleen 4. Pancreatic impression for tail of Pancrease. It lies between hilum of spleen and colic impression
	Diaphragmatic surface 1. Left Costophrenic recess 2. Left Lung 3. 9th to 11th ribs 4. Diaphragm

.

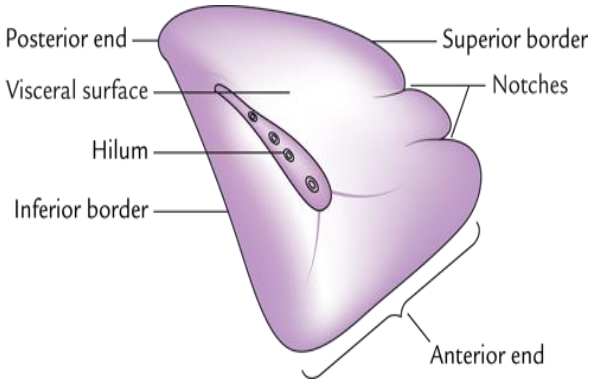

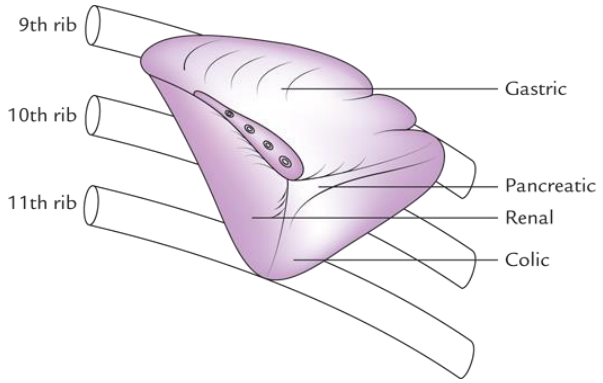

Blood supply : splenic vessels.

Nerve supply : coeliac plexus of sympathetic nerve

Microscopic structure

Spleen has thick capsule, sends septa into substance of spleen.

White pulp is aggregation of lymphocytes around the artery – peripheral lymphatic sheath made of 'T' lymphocytes. At some places it forms lymphatic nodules with germinal centers called as Malpighian bodies. They contain 'B' lymphocytes.

Red pulp forms the major part of spleen. It is made of lymphocytes arranged like branching and anastomosing cords along the sinusoids.

Spleen is the largest haemolymphoid organ.

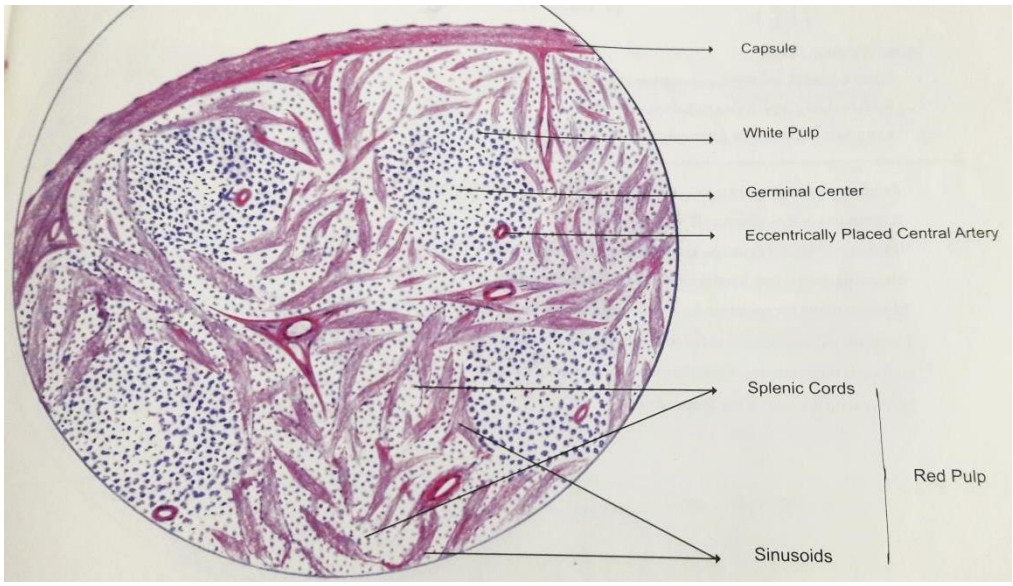

Applied anatomy

Slenomegaly : enlargement of spleen called splenomegaly. The common cause of splenomegaly are malaria, cirrhosis of liver, chronic myloid leukemia and kala azar.

Splenectomy : surgical removal of spleen.

THYMUS

It is a bilobed structure. The two lobes of thymus are connected across the midline by fibroareolar tissue. Situated in the superior and anterior mediastinum of thorax.

Extends : Lower pole of lateral lobe of thyroid gland to the 4th costal cartilage.

There after the thymus undergoes involution and is converted into fibro-fatty mass.

Blood supply : Internal thoracic and inferior thyroid arteries . Venous drainage by left brachiocephalic, internal thoracic and inferior thyroid veins.

Nerve supply : Vasomotor – stellate ganglion capsule by phrenic nerve.

Microscopic structure of thymus

Thymus is a primary lymphoid organ. It grows in size up to puberty and regress during adulthood .

Capsule sends incomplete septa into the paranchyma, dividing it into lobules.

Each lobule contains outer cortex and inner medulla.

Cortex is made up of densely packed small lymphocytes. And also contains macrophages for phagocytosis of degenerating lymphocytes and epitheliocytes which provide supporting meshwork.

Medulla of adjacents lobes are interconnected. It contains sparsely arranged large lymphocytes and epitheliocytes.

Degenerated epitheliocyte cell aggregation appear as concentric eosinophilic mass called Hassall's corpuscles in the medulla.

Epithelioid cells form reticular system of thymus and forms blood thymus barrier. Also produce hormones for proliferation and maturation of 'T' lymphocytes .

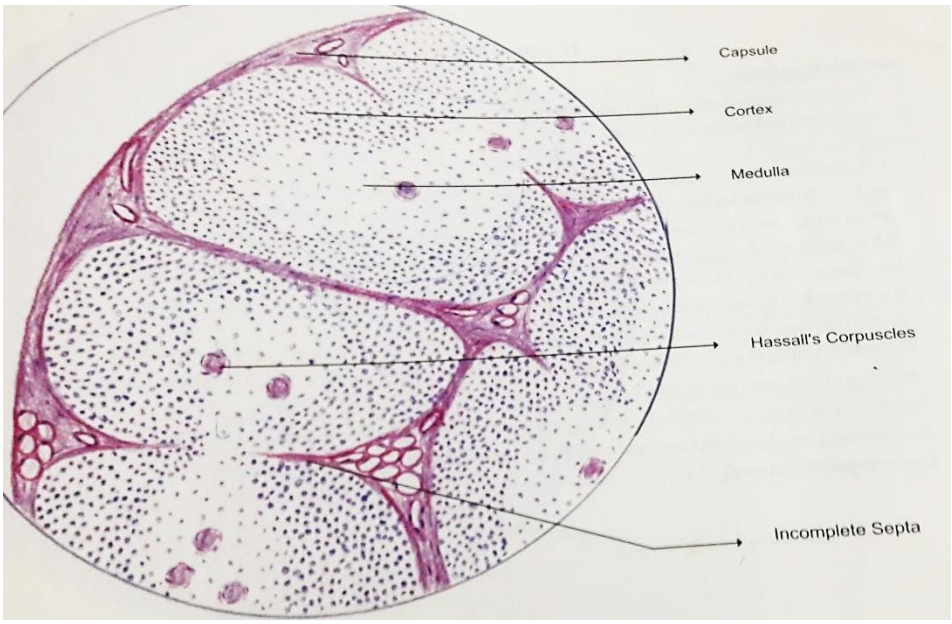

.

Applied anatomy

The epithelial cell tumor of thymus is known as thymoma and when large in size, can compress structures like trachea, esophagus and large veins in superior mediastinum.

PALATINE TONSIL

It is an almond – shaped mass of lymphoid tissue. It is situated in the tonsilar fossa of lateral wall of oropharynx.

External features and its relations

It consists of two surfaces, two borders and two poles.

Medial surface: Free and bulge to oropharynx and lined by non-keratinized stratified squamous epithelium. Tonsilar crypts are present and the largest and deepest crypt called crypta magna.

Lateral surface : Covered by fibro-fatty tissue of the pharyngeal wall. It is related by pharyngobasilar fascia, superior constrictor muscle & buccopharyngeal fascia.

Anterior border : Related to palatoglossal arch and palatoglossal muscle.

Posterior border : Related to palatopharyngeal arch and palatopharyngeal muscle .

Upper pole : Is related to soft palate

Lower pole : Is related to dorsal surface of posterior 1/3rd of tongue .

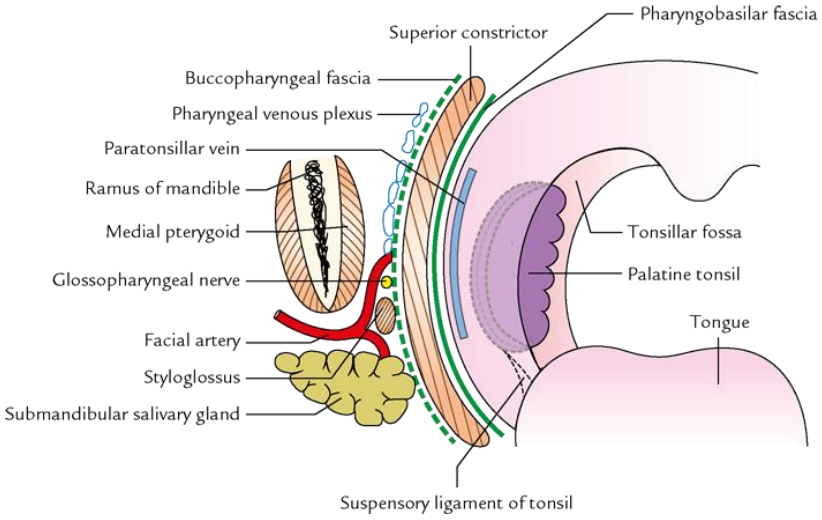

Arterial supply : Facial, lingual, ascending pharyngeal arteries

Venous drainage : Drains into paratonsillar vein which in turn drains into pharyngeal venous plexus

Lymphatic drainage : Upper deep cervical lymph node.

Nerve supply : Glossopharyngeal nerve and branch from sphenopalatine ganglion

Microscopic structure of tonsil

It belongs to mucosa-associated lymphoid tissue. It is active during early life.

Mucosa is lined by non-keratinized stratified squamous epithelium . Mucosa lining invaginate to form crypt, which are characteristic of palatine tonsil.

Lymphocytes are aggregated in the form of follicles with a central germinal center along the crypts. Follicles mainly contain 'B' lymphocytes. 'T' lymphocytes lies outside the follicle.
Mucous acini are seen in the deeper planes .

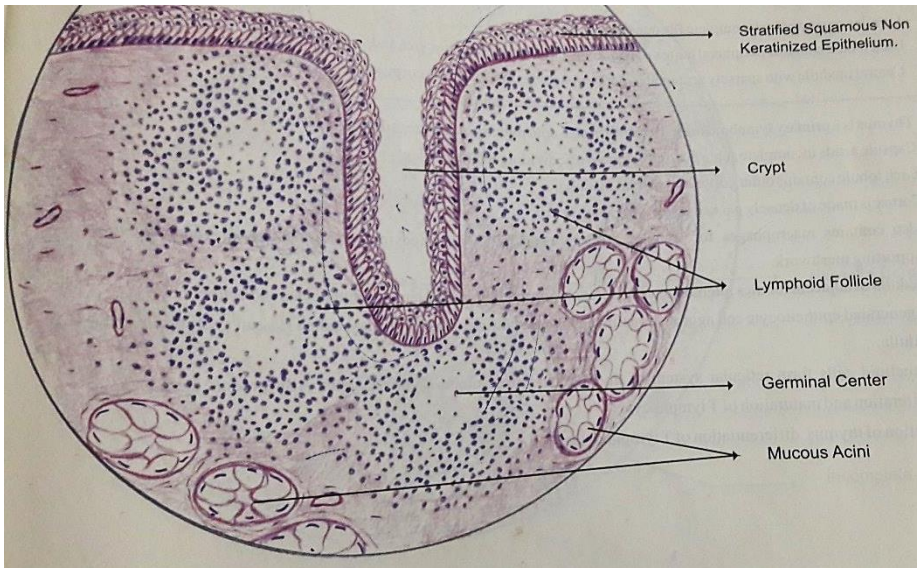

Applied anatomy

Acute infection of tonsil leads to tonsillitis .
Tonsillectomy : Surgical removal of tonsil called tonsillectom

Questions

1. Name the lymphoid organ. Explain any one of the lymphoid organ .
2. Palatine tonsil
3. Spleen
4. Thymus
5. Lymph node